

### SUPERIOR MESENTERIC VEIN THROMBOSIS AFTER THE WHIPPLE PROCEDURE: AN AGGRESSIVE, COMBINED TREATMENT APPROACH

Juan R. Sanabria, MD, MSc;\* Tadaaki Hiruki, MD;† David A. Szalay, MD;\* Véd Tandan, MD, MSc;\* Steven Gallinger, MD, MSc\*

It is now recognized that occlusion of the mesenteric veins not only may complicate a number of disease processes but may occur as a life-threatening complication after abdominal surgery. A 32-year-old woman had mesenteric venous thrombosis after resection of a duodenal inflammatory pseudotumour by pancreatoduodenectomy. She recovered fully after treatment, which consisted of thrombectomy, flushing with urokinase and intravenous administration of heparin. Papaverine infused for 4 days substantially improved bowel viability. Current concepts in mesenteric vein occlusion and the principles of clinical management are reviewed.

On reconnaît que l'occlusion des veines mésentériques peut non seulement compliquer de nombreux processus morbides, mais représenter une complication dangereuse après une intervention chirurgicale à l'abdomen. Une femme de 32 ans a été victime d'une thrombose d'une veine mésentérique après une résection d'une pseudotumeur inflammatoire au duodénum par pancréatoduodénectomie. Elle s'est rétablie complètement après le traitement, constitué d'une thrombectomie, d'un lavage à l'urokinase et de l'administration d'héparine par voie intraveineuse. Une infusion de papavérine pendant quatre jours a amélioré considérablement la viabilité de l'intestin. On passe en revue les concepts actuels de l'occlusion des veines mésentériques et les principes du traitement clinique.

Mesenteric thrombosis is a rare complication of abdominal surgery. Early diagnosis and prompt surgical treatment are needed to avoid the possibility of death. We report a case of superior mesenteric thrombosis, successfully treated by resection.

#### CASE REPORT

A 32-year-old woman presented with a 1-year history of vague epigas-

tric pain more evident after meals. Physical examination and biochemical investigations gave no abnormal results. Abdominal ultrasonography revealed an 8-cm echo-dense mass near the third portion of the duodenum. Initial CT, performed 1 year before surgery, revealed a solid mass located in the head of the pancreas with dilatation of the main pancreatic duct and compression of the third portion of the duodenum (Fig. 1A). An upper gastrointestinal series showed widen-

ing of the duodenum (Fig. 1B). Endoscopic images of the biliary-pancreatic ducts and examination of a percutaneous biopsy specimen were not helpful. Follow-up 6 and 12 months later (Fig. 1C) showed slow but definite enlargement of this poorly defined lesion. The patient was advised to have the mass excised because of concern that the mass might be malignant.

At operation, a large, hard mass was palpated around the uncinate process

From the \*Department of Surgery and †Department of Pathology, Mount Sinai Hospital, University of Toronto, Toronto, Ont.

Accepted for publication Aug. 20, 1996

Correspondence to: Dr. Steven Gallinger, Ste. 1225, Mount Sinai Hospital, 600 University Ave., Toronto ON M5G 1X5

© 1997 Canadian Medical Association (text and abstract/résumé)

of the pancreas. Further dissection showed a short segment of the superior mesenteric vein and the right colic vessels coursing directly through the tumour. The mass was resected en bloc as a Whipple procedure, including the right colon and 2 cm of the superior mesenteric vein. Primary mesenteric vein anastomosis was followed by pancreaticojejunostomy, choledochojejunostomy, gastrojejunostomy and enterocolostomy. Within 18 hours of surgery, the patient was in extremis

with profound abdominal distension, pain and hypotension. At laparotomy, thrombosis of the superior mesenteric vein was found at the site of the anastomosis, with clot extending up the root of the mesentery in almost all the medium-sized mesenteric vessels. The small bowel from the pancreatic anastomosis to the terminal ileum was very distended, thick-walled and black. No peristalsis and no arterial pulsations were noted. The mesenteric vein was entered at the site of the previous anastomosis, thrombectomized, flushed with urokinase (2500 units in 10 mL of normal saline) and reanastomosed. The patient was given intravenous heparin (1000 units/h with no loading

dose) and her abdomen closed by insertion of a Marlex mesh zipper for postoperative examination of the intestine.

Her condition remained stable and an angiogram obtained 12 hours after the second laparotomy demonstrated distal areas of nonperfusion (Fig. 2). Papaverine was given by continuous infusion (0.5 mL/min of a solution of 500 mg of papaverine in 250 mL of normal saline) through the arterial catheter placed at the root of the superior mesenteric artery. Daily examination of the abdomen showed steady improvement in bowel viability as judged by its colour progression from black to purple to dark red, and im-

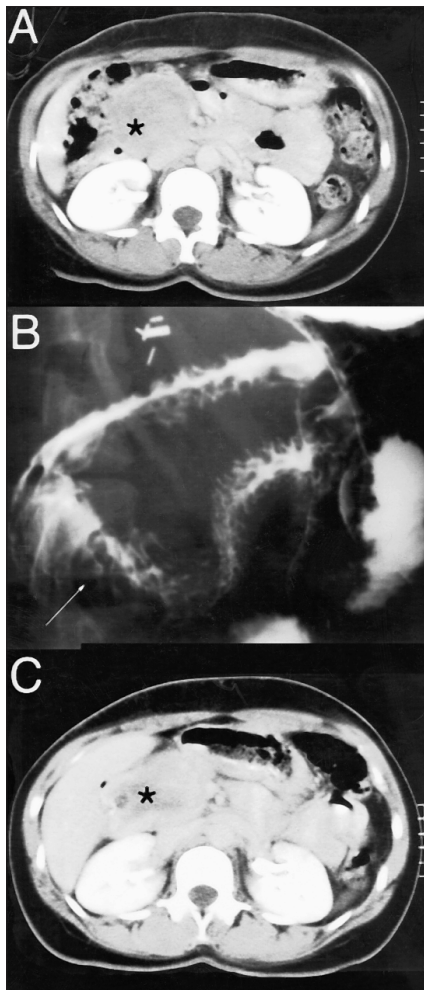


FIG. 1. CT scan of the abdomen (A) shows a well-defined mass (\*) localized near the second and third portions of the duodenum. Upper gastrointestinal series (B) shows widening of the duodenum. A follow-up CT scan at 1 year (C) shows a slight increase in the size of the mass with partial loss of tumour contours.

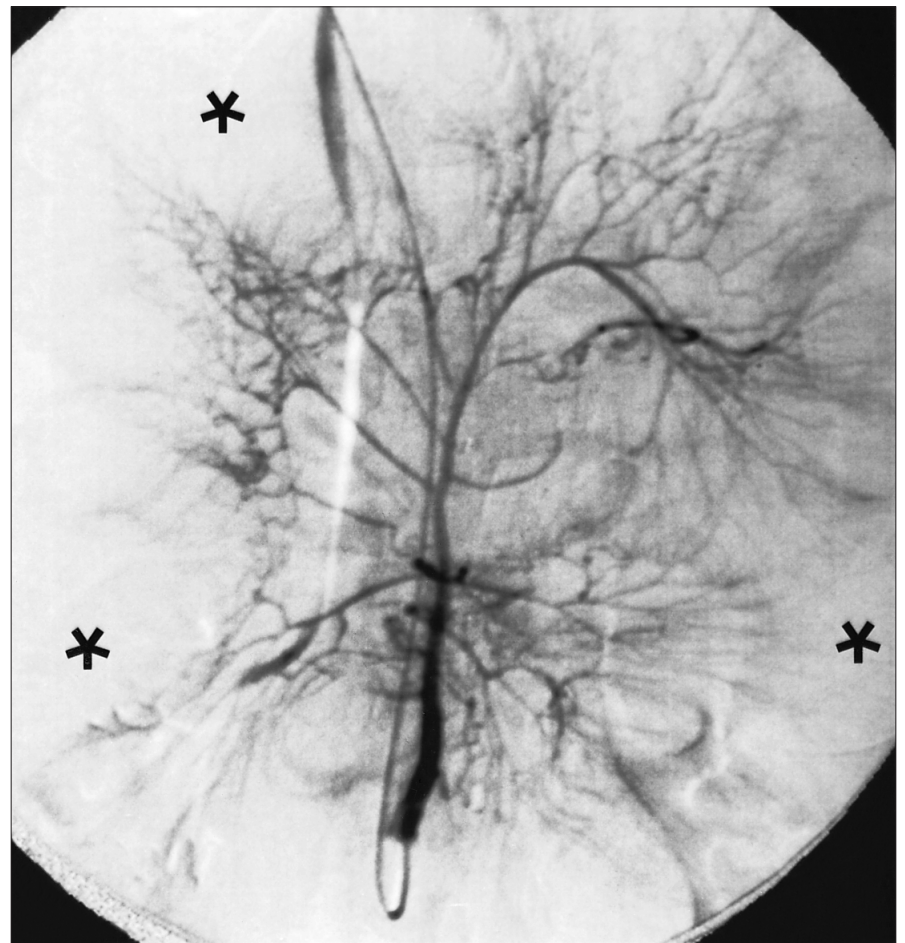
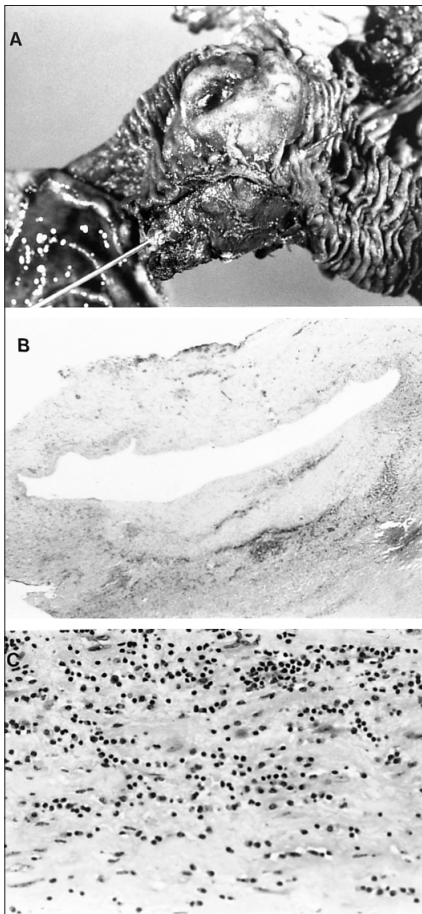

FIG. 2. Postoperative mesenteric angiogram 12 hours after thrombectomy of the superior mesenteric vein. The arterial phase demonstrates distal areas of poor perfusion (\*) due to small-size arterial vasospasm.

provement in peristalsis and pulsation of arcade vessels. The papaverine drip was stopped on the fifth day and her abdominal wall formally closed on the sixth day after the initial operation. She recovered fully and was discharged 28 days after admission. She returned to normal activities within 3 months of the initial operation and she was well at follow-up 3 years after surgery.



**FIG. 3.** (A) Operative specimen from the Whipple procedure. The resected portions of the duodenum showed the papillae and the tumour. A metallic stylet cannulates the papillae. (B) Low magnification of a transverse section from a resected mesenteric vein demonstrates invasion of the vessel wall by mesenchymal tissue (hematoxylin–eosin stain, original magnification  $\times 40$ ). (C) The microscopic morphologic features of the specimen include spindle-shaped cells in a loose myxoid stroma heavily infiltrated by inflammatory cells (hematoxylin–eosin stain, original magnification  $25 \times 20$ ).

**PATHOLOGICAL FINDINGS**

Sections of the duodenal mass showed uniform spindle-shaped cells in a loose myxoid stroma, which was heavily infiltrated by a mixed inflammatory component in which plasma cells predominated (Fig. 3). Thick bands of fibrous tissue were also present. The tumour undermined and lifted the overlying duodenal mucosa, which showed acute and chronic inflammation. There was no evidence of an epithelial neoplasm, foreign material or parasites. These features are compatible with an inflammatory fibroid polyp of the duodenal wall. The remainder of the resected organs was normal.

**DISCUSSION**

Intestinal infarction due to mesenteric vascular occlusion was first reported in the 15th century.<sup>1</sup> Other reports of intestinal gangrene due to thrombosis of the mesenteric vessels appeared during the 19th century,<sup>2</sup> including Elliot’s description in 1895 of a case in which operative intervention resulted in the patient’s recovery from this frequently lethal condition.<sup>1–5</sup> Mesenteric venous thrombosis was not described as a clinical entity distinct from arterial occlusion until 1935.<sup>2</sup> Schmidt and Schmidt<sup>6</sup> described a series of unselected autopsies (3785) and found an incidence of occluded superior or inferior mesenteric veins of 1.5%. In surgical series, mesenteric venous thrombosis accounts for 0.01% to 0.15% of admissions.<sup>7–10</sup> Mesenteric venous thrombosis has also been described after abdominal operations.<sup>2–5,9,11,12</sup> It has been estimated that mesenteric venous thrombosis occurs in 5% of patients after splenectomy.<sup>13</sup> Rare cases of venous thrombosis after pancreatoduodenectomy, as in the present case

report, have been described.<sup>14–16</sup>

Mesenteric venous thrombosis may differ from arterial occlusion in its clinical presentation and radiologic features. These differences are important because survival is as high as 88% if thrombectomy is carried out in patients with mesenteric venous thrombosis.<sup>4,17,18</sup> Nausea, vomiting and abdominal pain and distension with no other signs of obstruction appear to be the initial presentation in most patients along with significant compromise of mesenteric venous flow.<sup>4,17,18</sup> This postoperative complication should be considered early in a patient requiring unusually large amounts of fluids to maintain homeostasis, since the prognosis depends mainly on prompt intervention. Although angiography remains the standard diagnostic modality, CT may be helpful. Contrast-enhanced CT of the abdomen may show reduced contrast density in the superior mesenteric vein with or without portal vein thrombosis, dilated intestinal loops with wall thickening and the presence of peritoneal fluid.<sup>19</sup> Classically, risk factors for venous thrombosis include hypercoagulable states, endothelial trauma and stasis. In addition, intra-abdominal sepsis and cancer may predispose to this condition.<sup>4,17,18</sup>

After thrombectomy when the venous circulation has been re-established, systemic anticoagulation has been shown to decrease recurrence of the clot and possibly reduce mortality.<sup>14,18,20,21</sup> Nevertheless, a reliable approach to define the extent of bowel injury has not been developed. Early experiments in a canine model showed that infarction of the bowel wall after venous occlusion was a late event.<sup>22–24</sup> In addition, most animals died before necrosis became histologically evident in the cells of the muscularis propria.<sup>22–24</sup> However, the canine intestinal circulation differs from that of man in terms

of a more extensive collateral blood flow,<sup>17</sup> and it is difficult to differentiate between a state of reversible phlegmasia and actual gangrene of the bowel. Bowel judged to be nonviable by standard criteria (i.e., colour, peristalsis or vessel pulsation), may actually recover completely. As a result, authors advocate a conservative approach that avoids bowel resection during the initial operation.<sup>14,21,25,26</sup> A second-look operation has been shown to decrease the risk of unnecessary bowel resection, but the optimal timing of this second laparotomy is not clear.<sup>14,21,25,26</sup> We were impressed with the use of a Marlex mesh zipper, which allowed daily monitoring of the status of the intestine.

Arterial vasospasm plays an important role in mesenteric venous occlusion. Early experiments in dogs showed that vasospasm of smaller arteries usually accompanies occlusion of the main vessels in the mesenteric bed.<sup>22-24</sup> After release of the venous occlusion, the arteries remain in a state of moderate spasm for a considerable time (residual spasm).<sup>22</sup> Since the use of systemic vasodilators may have no effect on the mesenteric vessels of a patient with a strong stress response, the use of continuous intra-arterial infusion of vasoactive substances, such as papaverine, has been suggested.<sup>27</sup>

## CONCLUSIONS

Mesenteric thrombosis is a rare complication after abdominal surgery. Early recognition of this condition and prompt surgical intervention may prevent an often fatal outcome. Bowel recovery can be monitored daily by the insertion of a Marlex mesh zipper, which will avoid unnecessary bowel resections. Arterial infusion of vasoactive agents may decrease residual mesenteric arteriolar vasospasm.

## References

1. Laufman H, Scheinberg S. Arterial and venous mesenteric occlusion: analysis of forty-four cases. *Am J Surg* 1942;58:84-92.
2. McCune SW, Keshishian JM, Blades B. Mesenteric thrombosis following blunt abdominal trauma. *Ann Surg* 1952;135:606-14.
3. Jenson CB, Smith GA. A clinical study of 51 cases of mesenteric infarction. *Surgery* 1956;40:930-7.
4. Ostermiller W, Carter R. Mesenteric venous thrombosis secondary to polycythemia vera. *Am Surg* 1969;35:407-9.
5. Berry FB, Bougas JA. Agnogenic venous mesenteric thrombosis. *Ann Surg* 1950;132:450-74.
6. Schmidt T, Schmidt G. Übersicht 3785 Sektionsfalle mit Thrombosen und Massenthrombosen. *Beitr Klin Chir* 1967;214:348-55.
7. Whittaker LD, Pemberton J. Mesenteric vascular occlusion. *JAMA* 1938;3:21-8.
8. Warren S, Eberhard TP. Mesenteric vascular thrombosis. *Surg Gynecol Obstet* 1935;61:102-17.
9. Ottinger LW, Austen WG. A study of 136 patients with mesenteric infarction. *Surg Gynecol Obstet* 1967;124:251-62.
10. Hansen HJB, Christoffersen JK. Occlusive mesenteric infarction. A retrospective study of 83 cases. *Acta Chir Scand Suppl* 1976;472:103-8.
11. Schnug E. Ligation of the superior mesenteric vein. *Surgery* 1943;8:610-6.
12. Johnson CC, Baggenstoss AH. Mesenteric vascular occlusion: study of 99 cases of occlusion of veins. *Staff Meet Mayo Clin* 1949:628-36.
13. Bull SM, Zikria BA, Ferrer JM. Mesenteric venous thrombosis following splenectomy. Report of two cases. *Ann Surg* 1965;162:938-40.
14. Mergenthaler FW, Harris MN. Superior mesenteric vein thrombosis complicating pancreatoduodenectomy: successful treatment by thrombectomy. *Ann Surg* 1968;167:106-11.
15. Sigel B, Bassett JG, Cooper DR, Dunn MR. Resection of the superior mesenteric vein and replacement with a venous autograft during pancreatoduodenectomy. *Ann Surg* 1965;162:941-5.
16. Monge JJ, Judd S, Gage R. Radical pancreatoduodenectomy. *Ann Surg* 1964;160:711-21.
17. Grendell JH, Ockner RK. Mesenteric venous thrombosis. *Gastroenterology* 1982;82:358-72.
18. Abdu RA, Zakhour BJ, Dallis DJ. Mesenteric venous thrombosis, 1911-1984. *Surgery* 1987;101:383-8.
19. Clavien PA. Diagnosis and management of mesenteric infarction. *Br J Surg* 1990;77:601-3.
20. Trinkle JK, Rush BF, Fullmer M, Bryant LR, Rams J. The operative management of idiopathic mesenteric venous thrombosis with intestinal infarction. *Am Surg* 1969;35:338-41.
21. Levy PJ, Krausz MM, Manny J. The role of second-look procedure in improving survival time for patients with mesenteric venous thrombosis. *Surg Gynecol Obstet* 1990;170:287-91.
22. Laufman H, Martin WB, Tuell SW. The pattern of vasospasm following acute arterial and venous occlusions. *Surgery* 1948;87:641-51.
23. Donaldson JK, Stout BF. Mesenteric thrombosis. Arterial and venous types as separate clinical entities. A clinical and experimental study. *Am J Surg* 1935;29:208-17.
24. Polk HC. Experimental mesenteric venous occlusion: diagnosis and treatment of induced mesenteric venous thrombosis. *Ann Surg* 1966;163:432-44.
25. Singh RP, Shah RC, Lee ST. Acute mesenteric vascular occlusion: a review of thirty-two patients. *Surgery* 1975;78:613-7.
26. Khodadadi J, Rozenwajg J, Nacasch N, Schmidt B, Feuchtwanger MM. Mesenteric vein thrombosis. The importance of a second-look operation. *Arch Surg* 1980;115:315-7.
27. Boley SJ, Feinstein SR, Sammartano R, Brandt LJ, Sprayregen S. New concepts in the management of emboli of the superior mesenteric artery. *Surg Gynecol Obstet* 1981;153:561-9.